杏醫有限公司
GINKGOMED COMPANY

PLASTINATED SPECIMENS OF REGIONAL DISSECTION

Specimens are dissected from a real body and own their unique feature. Considering the individual difference of anatomical structures, any picture shown here should not be used as standard.

RDP0001
Layered Structure of Scalp

A piece of scalp is dissection to reveal the layered structure.

RDP0002
Layered Structure of Calvaria

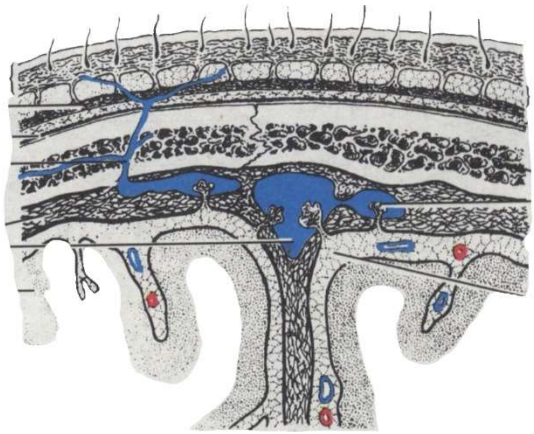

A piece of Calvaria with scalp is sectioned to reveal five layers structures on skull such as sklin, superficial fascia, epicranial aponeurosis, subaponeurotic space and periosteum.

RDP0003
Occipito-frontal Muscle with Vessels and Nerves

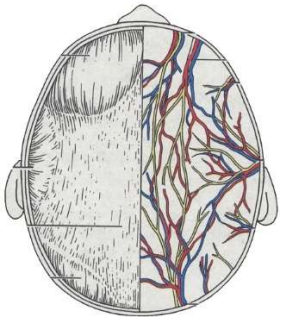

An upper half of the head is dissected to reveal occipito-frontal muscle, epicranial aponeurosis, and temporalis on one side, distribution of vessels and nerves on the other.

RDP0004
Sagittal Cut Half of Head and Neck Showing Superficial Structures

No. 5 An-He Road Sect. 2, 11 F-1, Taipei, Taiwan, R.O.C. http://www.ginkgomed.com.tw
Tel: +886-2-27041032 Fax: +886-2-27040645 e-mail：info@ginkgomed.com.tw

One half of head and neck is dissected to reveal muscles of facial expression and superficial layer of neck muscles with related vessels and nerves on it. The cut surface will show channeling from nostril, nasal cavity, mouth, oral cavity, larynx, pharynx, trachea and esophagus.

RDP0005
Mid-sagittal Cut of Head and Neck

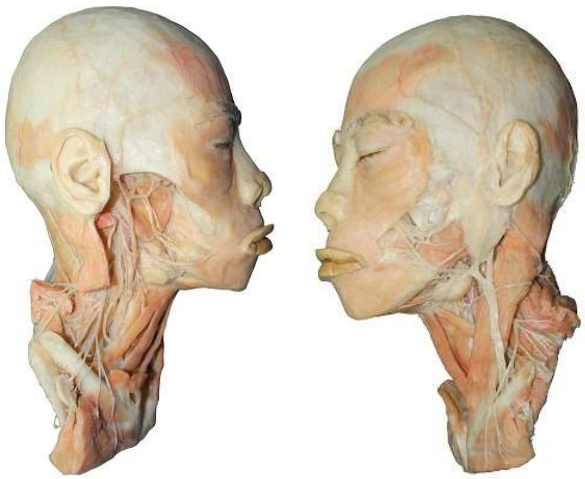

Head and neck is cut into two equal halves through a mid-sagittal cut. One half is dissected to reveal muscles of facial expression and muscles bordering triangles of neck on lateral surface. The other half is dissected to reveal muscles of mastication and deep muscles of neck on lateral surface. Further dissection is done on medial cut surface to reveal interior of nasal cavity, oral cavity, pharynx, esophagus, larynx and trachea.

RDP0006
Structures underneath Parotid

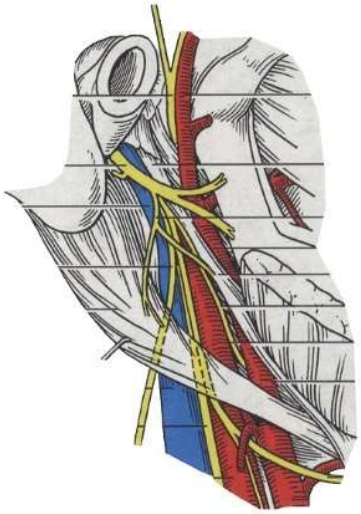

One half of head is dissected to reveal muscles, vessels and nerves by removing parotid gland.

RDP0007
Structures Underneath Masseter

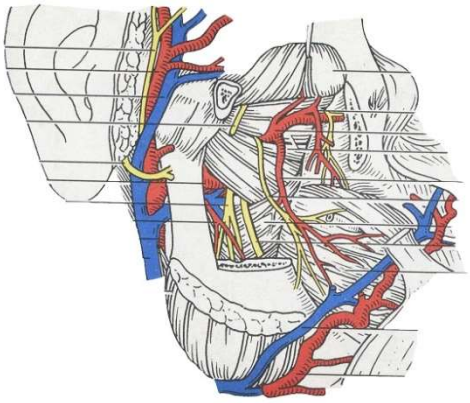

One half of head is dissected to reveal muscles, vessels and nerves by removing parotid gland. Further dissection is done to reveal deeper muscles, vessels and nerves by removing frontal part of mandibular ramus, zygonatic arch and masseter.

No. 5 An-He Road Sect. 2, 11 F-1, Taipei, Taiwan, R.O.C. http://www.ginkgomed.com.tw
Tel: +886-2-27041032 Fax: +886-2-27040645 e-mail：info@ginkgomed.com.tw

RDP0008

Structures Underneath Mandibular Ramus

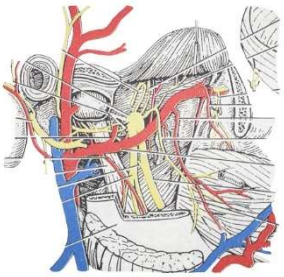

One half of head is dissected to reveal muscles, vessels and nerves by removing parotid gland. Further dissection is done to reveal paths of mandibular nerve and maxillary artery by removing the entire mandibular ramus and lateral pterygoid muscle. Content of the infratemporal fossa is fully exposed.

RDP0010

Tectorial Membrane and Posterior Longitudinal Ligament

The junction portion between head and neck is dissected to retain part of occipital bone and a segment of cervical column by removing most of soft tissue. Further dissection is done by a mid-sagittal cut to reveal tectorial membrane and posterior longitudinal ligament with other ligaments between bones.

RDP0011

Platysma and Superficial Structure of Neck

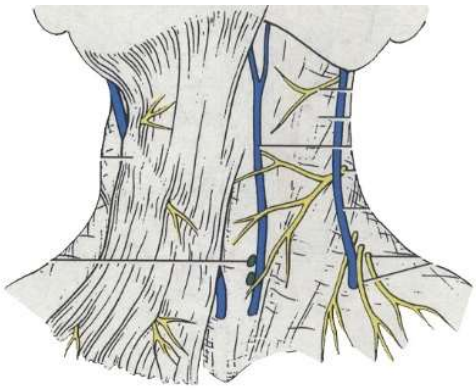

A head and neck is dissected to reveal covering of platysma on one side and superficial veins and nerves on the other.

RDP0012

Neck Triangles

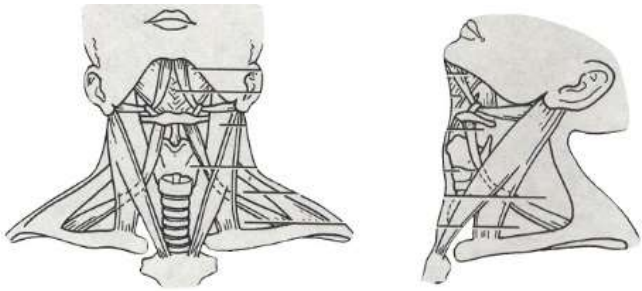

A head and neck is dissected to reveal all six neck triangles clearly such as submental triangle, submandibular triangle, carotid triangle, muscular triangle, occipital triangle and subclavian triangle.

No. 5 An-He Road Sect. 2, 11 F-1, Taipei, Taiwan, R.O.C. http://www.ginkgomed.com.tw
Tel: +886-2-27041032 Fax: +886-2-27040645 e-mail：info@ginkgomed.com.tw

RDP0013

Superficial Structure of Neck

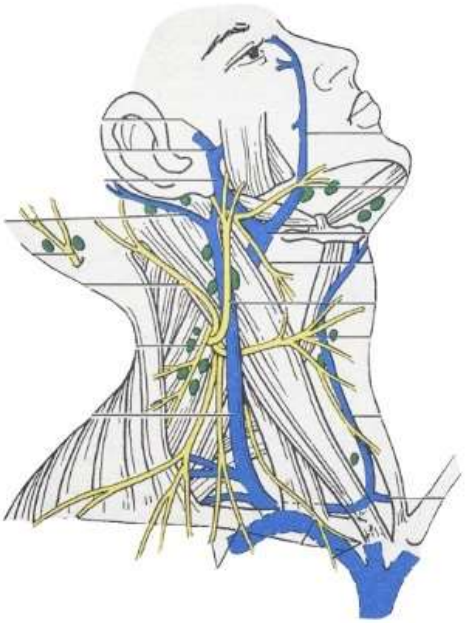

One half of head and neck is dissected to reveal muscles bordering neck triangles with superficial veins and nerves on them.

RDP0014

Content of SubmandibularTriangle

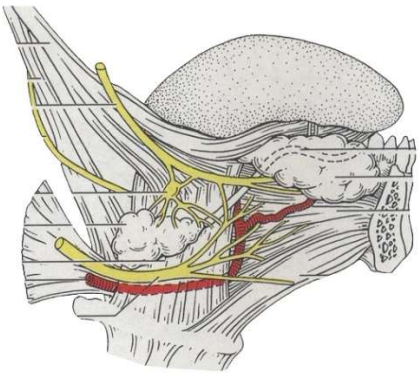

The region around mandible at one side is dissected to reveal structures bordered within the submandibular triangle.

RDP0015

Content of Carotid Triangle

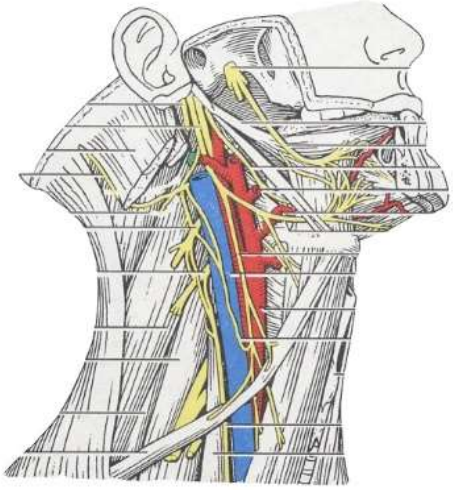

One half of head and neck is dissected to reveal structures bordered within the carotid triangle.

RDP0016

Carotid Arteries and Nerves

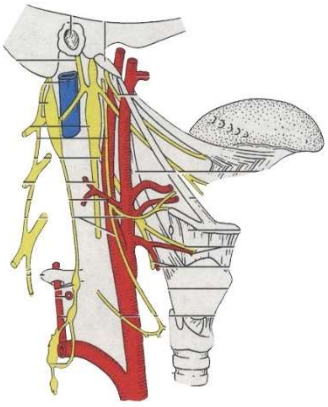

One half of neck is dissected to reveal common carotid artery branching into internal carotid artery and external carotid artery with its branches. Nerves running along with them are also shown.

No. 5 An-He Road Sect. 2, 11 F-1, Taipei, Taiwan, R.O.C. http://www.ginkgomed.com.tw
Tel: +886-2-27041032 Fax: +886-2-27040645 e-mail：info@ginkgomed.com.tw

RDP0017

Posterior Belly of Digastric Muscle

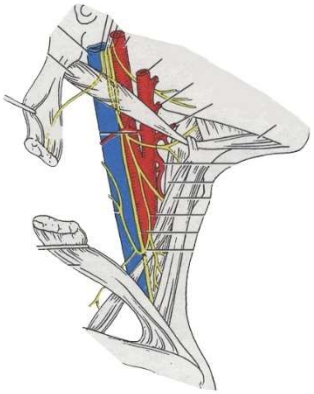

One half of head and neck is dissected to reveal posterior belly of digastrics muscle and structures around it.

RDP0018

Superior Layer of Anterior Neck

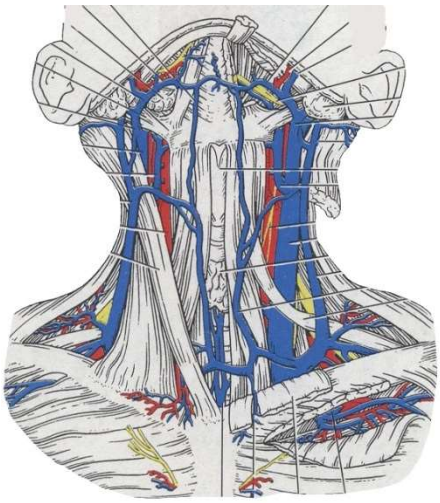

A head and neck is dissected to reveal external jugular vein and its tributaries at one side, internal jugular vein and its tributaries at the other. Carotid arteries and nerves are also visible.

RDP0019

Deep Layer of Anterior Neck

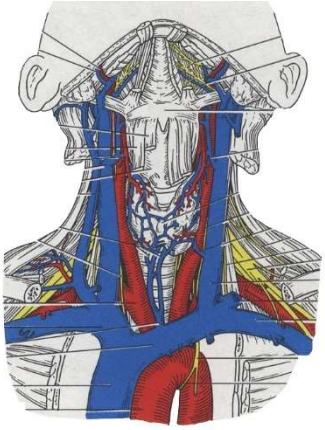

A head and neck is dissected to reveal carotid arteries, jugular veins and thyroid gland by removing muscles above them. Some nerves are also shown.

RDP0020

Arteries of Thyroid and Nerves to Larynx

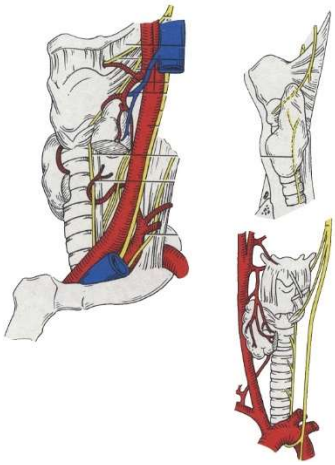

Larynx and a segment of trachea with thyroid gland are dissected to reveal arteries supplying thyroid and nerves to the larynx.

No. 5 An-He Road Sect. 2, 11 F-1, Taipei, Taiwan, R.O.C. http://www.ginkgomed.com.tw
Tel: +886-2-27041032 Fax: +886-2-27040645 e-mail：info@ginkgomed.com.tw

RDP0021
Veins of Thyroid

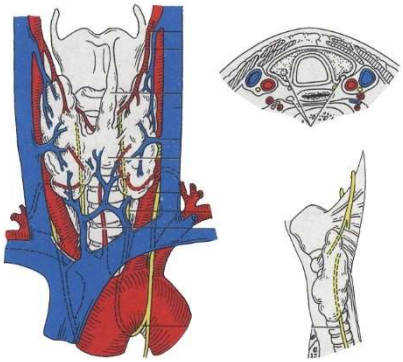

Larynx and a segment of trachea with thyroid gland are dissected to reveal venous drainages from thyroid to internal jugular veins and subclavian vein.

RDP0022
Root of Neck

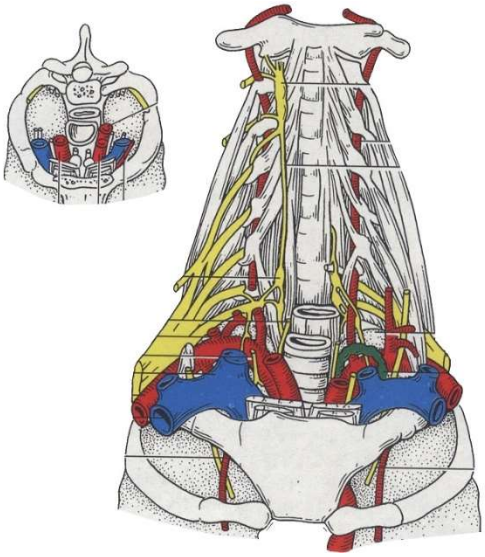

A neck is dissected to removes most of front muscles and vessels at the front and to reveal subclavian arteries, subclavian veins and brachial plexi at the root of neck.

RDP0023
Anterior Scalene Muscle

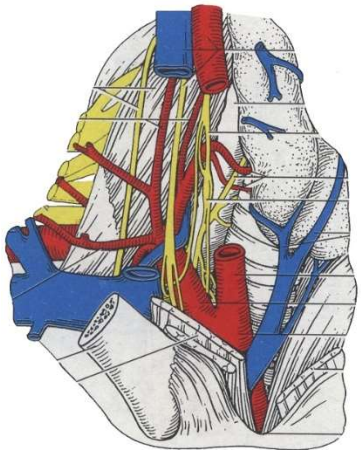

A neck is dissected to removes most of muscles and vessels at the front. Anterior scalene muscles is revealed with vessels and nerves around it.

RDP0024
Content of Vertebral Triangle

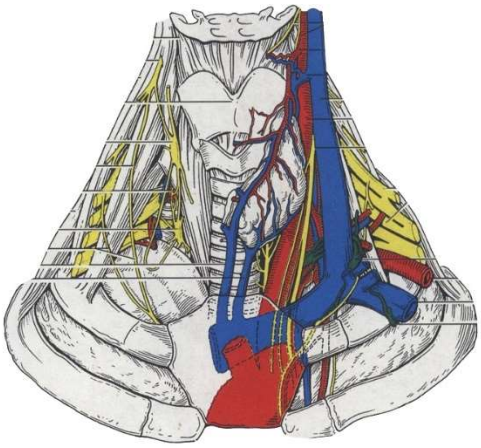

A neck is dissected to reveal structures bordered by long muscles of neck medially, anterior scalene muscle laterally and subclavian artery at the button.

No. 5 An-He Road Sect. 2, 11 F-1, Taipei, Taiwan, R.O.C. http://www.ginkgomed.com.tw
Tel: +886-2-27041032 Fax: +886-2-27040645 e-mail：info@ginkgomed.com.tw

RDP0025

Content of Occipital Triangle

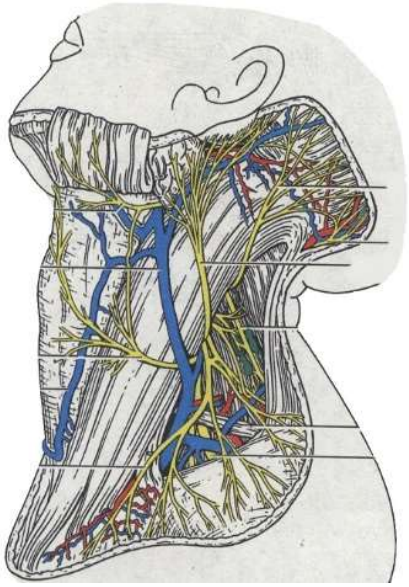

A neck is dissected to reveal structures bordered by sternocleidomastoid, trapezius and omohyoid muscles.

RDP0026

Content of Supraclavicular Triangle

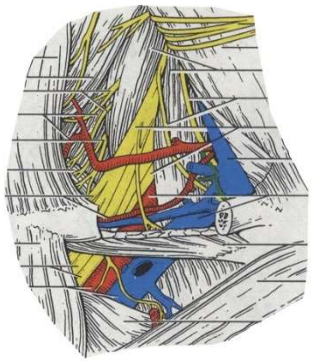

A neck is dissected to reveal structures bordered by bordered by sternocleidomastoid muscle, omohyoid muscle and clavicle.

RDP0028

Formation of Axillary Fossa

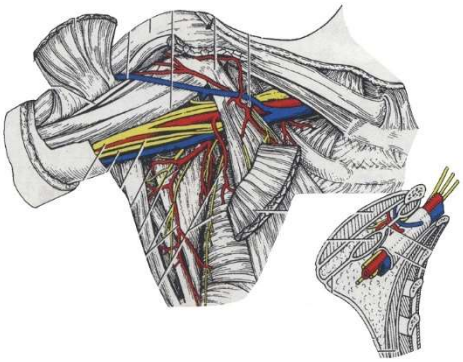

A region surrounding the axillary fossa is dissected to reveal muscular wall forming the fossa.

RDP0029

Dissection of Axillary Walls and Content

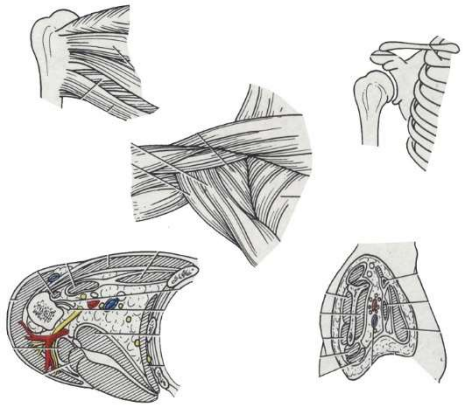

A region surrounding the axillary fossa, including the shoulder and upper thoracic wall, is dissected to reveal muscular wall forming the fossa. Vessels and nerves within the fossa, such as axillary artery, axillary vein and brachial plexus are also shown. The shoulder joint is dissected to expose with intact capsule.

No. 5 An-He Road Sect. 2, 11 F-1, Taipei, Taiwan, R.O.C. http://www.ginkgomed.com.tw
Tel: +886-2-27041032 Fax: +886-2-27040645 e-mail：info@ginkgomed.com.tw

RDP0030

Paths of Vessels and Nerves in Upper Limb

An upper limb, including shoulder, arm, forearm and hand, is dissected from the body. Further dissection is done to expose paths of arteries, veins and nerves at several locations where the skin and muscles are removed.

RDP0031

Dissection of Cubital Fossa and Elbow

A region around the elbow is dissected to reveal muscular borders of cubital fossa and related vessels and nerves. Elbow joint is kept intact.

RDP0032

Dissection of Hand

A hand is dissected to reveal muscles, arteries and nerves within the hand.

RDP0033

Superficial Muscles of Anteriolateral Abdominal Wall

An anteriorlateral abdominal wall is dissected to reveal external oblique muscle and rectal sheath at one side, internal oblique, transverse oblique, rectal abdominal muscles at the other.

No. 5 An-He Road Sect. 2, 11 F-1, Taipei, Taiwan, R.O.C. http://www.ginkgomed.com.tw
Tel: +886-2-27041032 Fax: +886-2-27040645 e-mail：info@ginkgomed.com.tw

RDP0034

Deep Muscles of Anterio-lateral Abdominal Wall

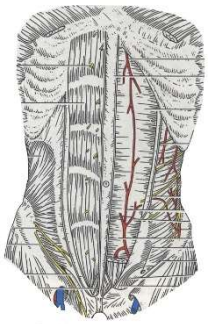

An anteriorlateral abdominal wall is dissected to reveal internal oblique and rectal abdominal muscles at one side, transverse oblique muscle and the posterior layer of rectal sheath at the other, Some related arteries and nerves are also shown.

RDP0035

Superficial Layer of Inguina and Femoral Triangle

A segment of thigh root is dissected from the body. Further dissection is done to reveal the spermatic cord piercing into the superficial inguinal ring and the femoral triangle covered by fascia.

RDP0036

Intermediate Layer of Inguina and Femoral Triangle

A segment of thigh root is dissected from the body. Further dissection is done to reveal the spermatic cord in the inguinal canal and piercing into internal oblique muscle. The content of the femoral triangle is seen to be covered by femoral sheath.

RDP0037

Deep Layer of Inguina and Femoral Triangle

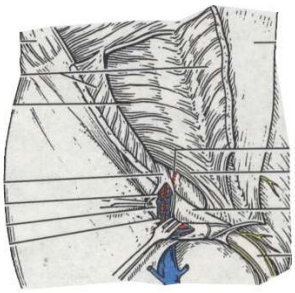

A segment of thigh root is dissected from the body. Further dissection is done to reveal the spermatic cord passing through the inguinal canal and piercing into transverse abdominis muscle. The content of the femoral triangle such as femoral artery, femoral vein and femoral nerve can be seen.

No. 5 An-He Road Sect. 2, 11 F-1, Taipei, Taiwan, R.O.C. http://www.ginkgomed.com.tw
Tel: +886-2-27041032 Fax: +886-2-27040645 e-mail：info@ginkgomed.com.tw

RDP0038

Attachment of Lessor Omentum

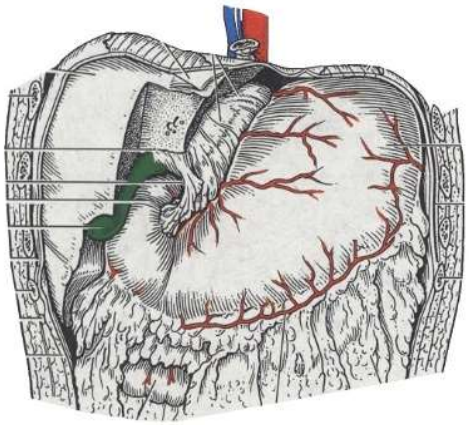

An upper part of the abdomen is dissected to reveal stomach located underneath the diaphragm with lesser omentum attached on it. Part of the greater omentum may also be shown.

RDP0039

Vessels Supplying Stomach

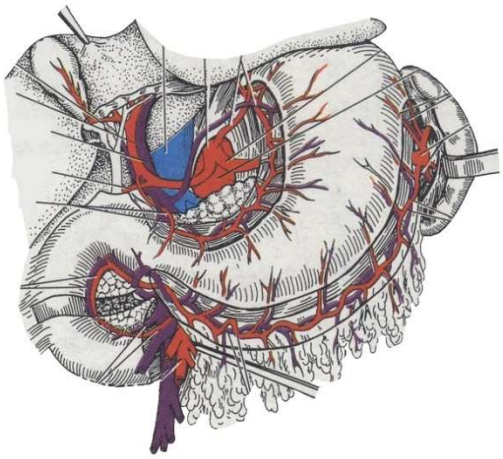

An upper part of the abdomen is dissected to reveal stomach between liver and spleen. Artreries supplying to the stomach are shown to be originated from celiac trunk.

RDP0040

Vagus Nerve to Stomach

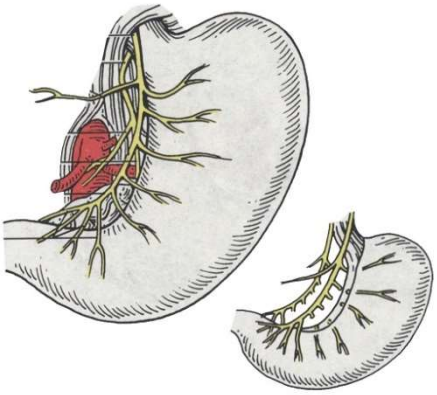

An upper part of the abdomen is dissected to reveal stomach located underneath the diaphragm with vagus nerve branching along the lesser curvature of the stomach.

RDP0041

Structures around Duodenum

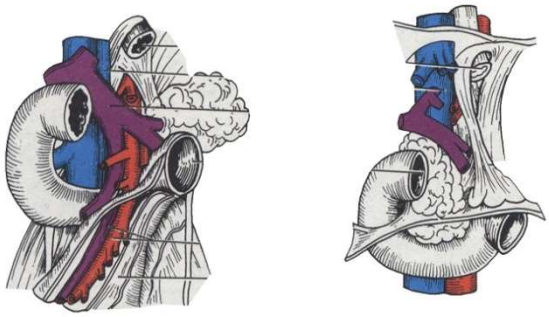

A duodenum is dissected to reveal structures around it such as inferior vena cava, portal vein, superior mesenteric artery, superior mesenteric vein and mesentery.

No. 5 An-He Road Sect. 2, 11 F-1, Taipei, Taiwan, R.O.C. http://www.ginkgomed.com.tw
Tel: +886-2-27041032 Fax: +886-2-27040645 e-mail：info@ginkgomed.com.tw

RDP0042

Duodenum with Pancreas

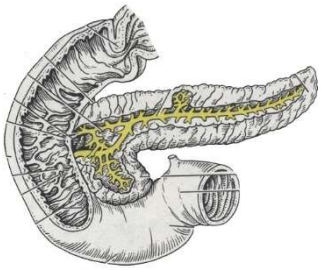

A duodenum with pancreas is dissected to reveal pancreatic ducts opening into major and minor papillae on duodenal wall.

RDP0043

Arteries to Duodenum

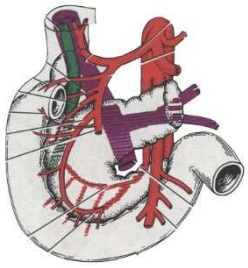

A duodenum with pancreas is dissected to reveal arterial supply from the celiac trunk.

RDP0044

Veins from Duodenum

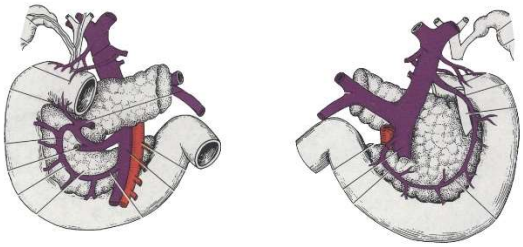

A duodenum with pancreas is dissected to reveal venous drainage to superior mesenteric vein and portal vein.

RDP0045

Small and Large Intestines

A large range of intestine from jejunum, ileum, ascending colon, transverse colon, descending colon to sigmoid colon is dissected to reveal external features. Several windows are cut open on each part of the intestine to show the interior.

RDP0046

Porta Hepatics

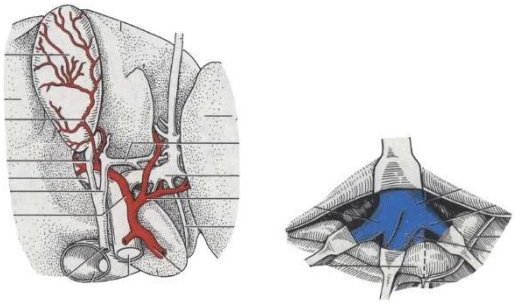

A liver is dissected to reveal the formation of hepatic pedicle at the porta hepatics, including bile ducts, portal vein and hepatic artery.

No. 5 An-He Road Sect. 2, 11 F-1, Taipei, Taiwan, R.O.C. http://www.ginkgomed.com.tw
Tel: +886-2-27041032 Fax: +886-2-27040645 e-mail：info@ginkgomed.com.tw

RDP0047
Gallbladder with Bile Ducts

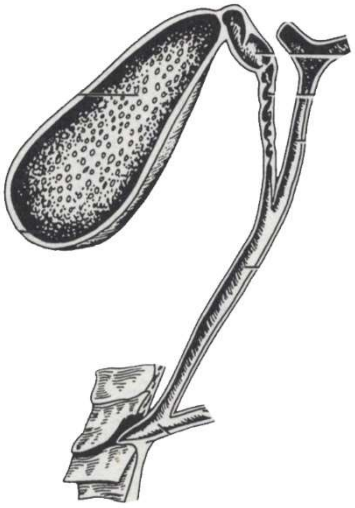

A gallbladder is dissected to reveal its features connection with common bile duct through cystic duct.

RDP0048
Structures around Pancreas

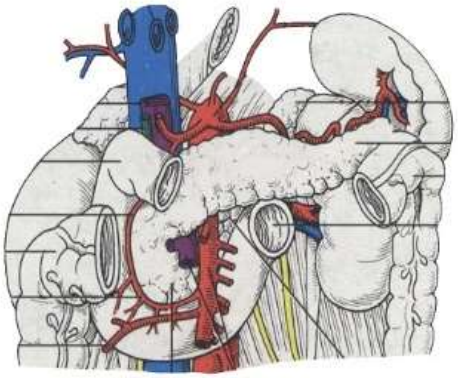

An upper abdomen is dissected to expose pancreas between duodenum and spleen by removing stomach, transverse colon. Related arteries and veins are also shown.

RDP0049
Peritoneum on Posterior Abdominal Wall

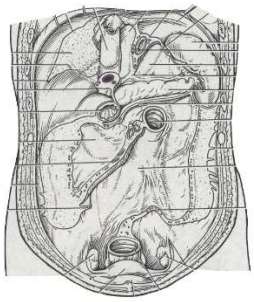

An abdominal portion of torso is dissected to remove most of organs but leave retroperitoneal organs intact. Peritoenum covering the posterior abdominal wall can be seen to form radix of mesentery and mesenteric sinuses.

RDP0050
Retroperitoneal Structures

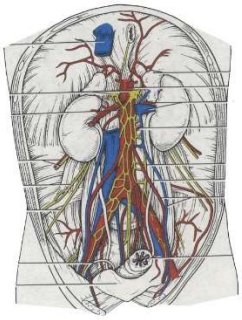

An abdominal portion of torso is dissected to remove most of organs but leave retroperitoneal organs intact. After removing peritoenum covering the posterior abdominal wall and some retroperitoneal organs, diaphragmatic muscles, muscles of the posterior abdominal wall, kidneys and related vessels and nerves are revealed.

No. 5 An-He Road Sect. 2, 11 F-1, Taipei, Taiwan, R.O.C. http://www.ginkgomed.com.tw
Tel: +886-2-27041032 Fax: +886-2-27040645 e-mail：info@ginkgomed.com.tw

RDP0051

Muscles of Pelvic Wall

One half of pelvis is dissected to reveal muscles forming the pelvic wall.

RDP0052

Structures within Male Superficial Perineal Space

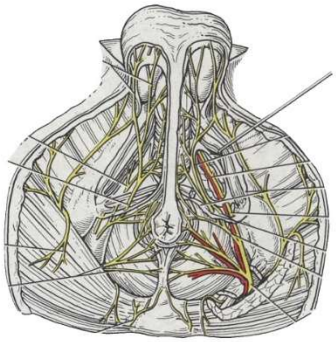

A torso part from the lumbar to the groin is dissected from the male body, followed by removing all viscera within the male pelvic cavity. Further dissection is done to expose the muscular structure of the male perineum and superficial perineal space. Within the space, superficial transverse perineal muscle, perineal artery, perineal nerve, pudendal nerve and their branches are revealed.

RDP0053

Structures within Male Deep Perineal Space

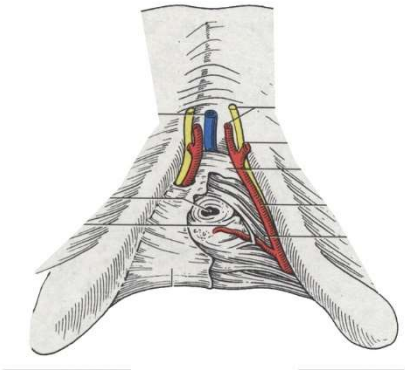

A torso part from the lumbar to the groin is dissected from the male body, followed by removing all viscera within the male pelvic cavity. Further dissection is done to expose the deep perineal space. Within the space, sphincter urethrae, urogenial diaphragm and related vessel and nerves are revealed.

RDP0054

Structures within Female Superficial Perineal Space

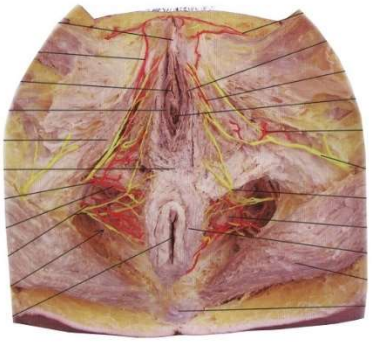

The dissection is similar to that of RDP0052 but done on female one.

No. 5 An-He Road Sect. 2, 11 F-1, Taipei, Taiwan, R.O.C. http://www.ginkgomed.com.tw
Tel: +886-2-27041032 Fax: +886-2-27040645 e-mail：info@ginkgomed.com.tw

RDP0055

Structures within Female Deep Perineal Space

The dissection is similar to that of RDP0053 but done on female one.

RDP0056

Layered Structure of Scrotum

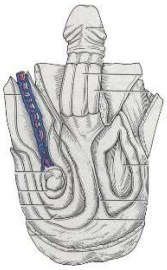

Scrotum with penis is dissected to reveal its layered structure.

RDP0057

Dorsal Penile Vessels and Nerves

A penis is dissected to reveal single dorsal penile deep vein, paired dorsal penile arteries, paired dorsal penile nerves and their branches.

RDP0058

Paths of Vessels and Nerves in Lower Limb

A lower limb, including half pelvis, thigh, leg and foot, is dissected from the body. Further dissection is done to expose paths of arteries, veins and nerves at several locations where the skin and muscles are removed.

RDP0059

Dissection of Popliteal Fossa and Knee

A region around the knee is dissected to reveal muscular borders of popliteal fossa and related vessels and nerves.

No. 5 An-He Road Sect. 2, 11 F-1, Taipei, Taiwan, R.O.C. http://www.ginkgomed.com.tw
Tel: +886-2-27041032 Fax: +886-2-27040645 e-mail：info@ginkgomed.com.tw

RDP0060

Dissection of Foot

A foot is dissected to reveal muscles, arteries and nerves within the foot.

No. 5 An-He Road Sect. 2, 11 F-1, Taipei, Taiwan, R.O.C. http://www.ginkgomed.com.tw
Tel: +886-2-27041032 Fax: +886-2-27040645 e-mail：info@ginkgomed.com.tw